



# Incidence and Outcomes of Repositioning Surgery to Correct Misalignment of Toric Intraocular Lenses

Tetsuro Oshika, MD,<sup>1</sup> Mikio Inamura, MD,<sup>2</sup> Yasushi Inoue, MD,<sup>3</sup> Tsutomu Ohashi, MD,<sup>4</sup> Toru Sugita, MD,<sup>5</sup> Yoshifumi Fujita, MD,<sup>6</sup> Kazunori Miyata, MD,<sup>7</sup> Shinichiro Nakano, MD<sup>8</sup>

**Purpose:** To analyze the incidence and appropriate timing of repositioning surgery to correct misalignment of acrylic foldable toric intraocular lenses (IOLs).

**Design:** Retrospective, multicenter case series.

**Participants:** Patients who had undergone phacoemulsification and implantation of toric IOL at 8 surgical sites.

**Methods:** Patient charts were reviewed to collect data on repositioning surgery of toric IOLs.

**Main Outcome Measures:** Incidence, timing, and outcomes of repositioning surgery.

**Results:** Among 6431 eyes implanted with toric IOLs, 42 eyes (0.653%) of 42 patients underwent repositioning surgery at an average of  $9.9 \pm 7.5$  days (range, 0–30 days) after IOL implantation. The repositioning surgery significantly reduced misalignment from  $32.9^\circ \pm 15.7^\circ$  to  $8.8^\circ \pm 9.7^\circ$  ( $P < 0.001$ ), which was measured at  $7.6 \pm 5.0$  weeks postoperatively. Refractive cylinder was significantly reduced from  $2.4 \pm 1.1$  diopters (D) to  $1.1 \pm 0.8$  D ( $P < 0.001$ ). There was a significant negative correlation between the interval from cataract surgery to repositioning procedure and the degree of residual misalignment ( $r = -0.439$ ,  $P < 0.001$ ). The residual misalignment was  $13.1^\circ \pm 13.5^\circ$  when the repositioning surgery was performed within 6 days after cataract surgery, whereas the residual misalignment was  $6.3^\circ \pm 5.9^\circ$  when the IOL was repositioned 7 days or later ( $P < 0.001$ ). In 2 eyes that were treated within 24 hours after cataract surgery, the IOL re-rotated significantly, and additional surgical intervention was required.

**Conclusions:** Toric IOLs were repositioned in 0.653% of cases. A relationship was found between the timing of repositioning surgery and surgical outcome. These data suggest that repositioning surgery should be performed 1 week after IOL implantation. *Ophthalmology* 2018;125:31–35 © 2017 by the American Academy of Ophthalmology

With the advent of toric intraocular lens (IOL) technology, an increasing number of surgeons attempt to correct preexisting corneal astigmatism at the time of cataract surgery to enhance the postoperative unaided vision of patients. Evidence has been mounting that toric IOLs provide better uncorrected distance visual acuity, greater spectacle independence, and lower degrees of residual astigmatism than nontoric IOLs.<sup>1,2</sup> Crucial to the efficacy of toric IOLs is the precise positioning of the lens in relation to the intended alignment axis.<sup>1</sup> Toric IOL misalignment less than  $10^\circ$  changes the eye's refraction by less than 0.50 diopters (D), and thus is not a problem for satisfactory astigmatism correction.<sup>3</sup> However, large axis misalignment will eliminate the corrective effect of toric IOLs,<sup>4</sup> and surgical interventions are sometimes required to realign the IOL.

A previous study reported 3 cases of surgical repositioning of AcrySof toric IOL (Alcon Laboratories, Inc., Fort Worth, TX) due to a misalignment of more than  $15^\circ$  off axis, with an overall rate of 1.1% (3/263 eyes).<sup>5</sup> A multicenter, 1-year study showed that among 256 eyes implanted with AcrySof toric IOLs, reorientation of the lens axis was needed in 1 eye.<sup>6</sup> Other studies reported that the incidence

of repositioning surgery after AcrySof toric IOL implantation was 2 of 111 eyes,<sup>7</sup> 4 of 122 eyes,<sup>8</sup> 1 of 82 eyes,<sup>9</sup> and 7 of 378 eyes.<sup>10</sup> Of 172 eyes implanted with TECNIS toric IOLs (Abbott Medical Optics, Inc., Santa Ana, CA), realignment surgery was performed in 4 eyes (2.3%) during a 6-month clinical trial.<sup>11</sup> TECNIS toric IOLs have been repositioned in 4 of 174 eyes<sup>12</sup> and 2 of 27 eyes.<sup>13</sup> In a prospective multicenter clinical trial that included 93 eyes that were implanted with a hydrophobic acrylic toric IOL (TC2, HOYA, Tokyo, Japan), 3 lenses were repositioned.<sup>14</sup> Except for these small case reports, however, there has been no large-scale clinical investigation on the rate and outcomes of toric IOL repositioning surgery. We conducted the present study to assess the incidence and proper timing of repositioning surgery to correct misalignment of acrylic foldable toric IOLs of several manufacturers.

## Methods

We retrospectively collected the data of patients who had undergone toric IOL repositioning surgery from May 2013 to April 2016

at 8 surgical sites in Japan. By reviewing the medical files, records were analyzed on preoperative keratometry, axial length, model of toric IOLs, power of IOLs, target toric axis, degree of axis misalignment, direction of axis misalignment (clockwise or counterclockwise), timing of repositioning surgery, and outcomes of repositioning surgery including final axis orientation and degree of residual misalignment.

Because this was a retrospective study, surgical procedures, examination methods, and indication of repositioning surgery were not standardized before surgery. In general, the following procedures were used. At the time of initial cataract surgery, the reference and alignment axes were manually marked on the eye. The marking techniques were not identical among the surgeons with different spatulas or markers used, but otherwise there were substantial similarities. Before surgery, with the patients in an upright seated position to avoid cyclotorsion errors, the corneal limbus of each eye was marked along the principal meridians at the slit lamp. At the beginning of surgery, the steepest meridian of the corneal limbus was identified and marked with a toric IOL marker. After phacoemulsification and removal of cortical materials, a toric IOL was implanted in the capsular bag using an injector. The IOL was rotated to its final position by aligning the reference marks on the IOL with the limbal axis marks. The incision was not sutured. Limbal relaxing incision or astigmatic keratotomy was not performed.

After surgery, IOL alignment was assessed at each postoperative visit. The misalignment was defined as the difference between the preoperatively calculated IOL axis and real IOL axis after surgery. Postoperative orientation of the toric IOL was measured on slit-lamp digital retroillumination photographs taken with the eyes fully dilated. Repositioning surgery was indicated when the surgeons judged that visual function of the patients would be improved by correcting IOL axis misalignment and the patients consented to the secondary surgical intervention. In the repositioning surgery, we attempted to realign the toric IOL axis to the orientation planned at the time of cataract surgery. Capsular tension ring was not used in any cases.

The study protocol was reviewed and approved by the Institutional Review Board or the Ethical Review Committee of participating institutions. This study was conducted in accordance with the Declaration of Helsinki, the Ministerial Ordinance Regarding Good Clinical Practice Principles for Medical Devices (2005, Ministry of Health, Labour and Welfare Ordinance No. 36). All patients provided written informed consent.

Paired variables, such as data before and after repositioning surgery, were statistically compared using the Student *t* test. Unpaired data were compared using the unpaired *t* test, and the relation between continuous variables was assessed by means of the Pearson's correlation coefficient. For assessment of data among 3 or more groups, such as among different IOL models, the multiple comparison test was used, that is, 1-way analysis of variance. The incidence of repositioning surgery among different IOL groups was compared with the Kruskal-Wallis test, and the ratio of clockwise and counterclockwise rotation was compared using the chi-square test. All statistical tests were 2 sided, and a *P* value of less than 0.05 was considered significant. The numeric data are presented as the mean  $\pm$  standard deviation unless otherwise noted. Statistical analysis was performed using SPSS software version 22 (IBM Corp, Armonk, NY).

## Results

Among 6431 eyes implanted with toric IOLs at the 8 surgical sites, 42 eyes (0.653%) of 42 patients underwent repositioning surgery. The basic characteristics of these 42 patients are summarized in

Table 1. Patient Characteristics

Age, yrs	
Mean (SD)	69.6 (10.4)
Range	35–86
Male/female	18/24
Axial length (mm)	
Mean (SD)	24.3 (1.9)
Range	22.0–30.3
IOL power (D)	
Mean (SD)	19.1 (4.9)
Range	6.0–24.5
Preoperative corneal cylinder (D)	
Mean (SD)	2.17 (0.73)
Range	1.0–4.2
WTR/ATR/oblique	12/24/6

ATR = against-the-rule astigmatism (steep corneal cylinder axis was between 0° and 30° or 150° and 180°); oblique = oblique astigmatism (steep corneal cylinder axis was between 30° and 60° or 120° and 150°); D = diopters; IOL = intraocular lens; SD = standard deviation; WTR = with-the-rule astigmatism (steep corneal cylinder axis was between 60° and 120°).

Table 1, and a histogram of axial length is shown in Figure 1. The average axial length was  $24.3 \pm 1.9$  mm (range, 22.0–30.3 mm), and the axial length was longer than 25.0 mm in 11 eyes (26.2%). The average degree of misalignment was  $32.9^\circ \pm 15.7^\circ$  (range, 10°–74°), including 11 eyes with clockwise rotation (misalignment =  $30.7^\circ \pm 19.3^\circ$ ; range, 10°–69°) and 31 eyes with counterclockwise rotation (misalignment =  $33.6^\circ \pm 14.5^\circ$ ; range, 13°–74°). Refractive cylinder was  $2.4 \pm 1.1$  diopters (D) (range, 0.5–6.5 D).

The repositioning surgery was performed at an average of  $9.9 \pm 7.5$  days (range, 0–30 days) after the primary cataract surgery. There were no complications during and after the repositioning surgery. The final measurement of alignment after repositioning was obtained at  $7.6 \pm 5.0$  weeks postoperatively. Misalignment was reduced by  $24.1^\circ \pm 16.5^\circ$  (range,  $-2^\circ$ – $72^\circ$ ) to  $8.8^\circ \pm 9.7^\circ$  (range, 0°–40°) (*P* < 0.001). Refractive cylinder was significantly reduced to  $1.1 \pm 0.8$  D (range, 0–3.25 D) (*P* < 0.001). There was a significant negative correlation between the interval from cataract surgery to repositioning procedure and the degree of residual misalignment (Fig 2) (Pearson *r* =  $-0.439$ , *P* < 0.001). The degree of residual misalignment was  $13.1^\circ \pm 13.5^\circ$  when the repositioning surgery was done within 6 days after cataract surgery; a misalignment of  $6.3^\circ \pm 5.9^\circ$  remained when the IOL was repositioned 7 or more days after cataract surgery (Fig 3) (*P* < 0.001). The degree of misalignment before the repositioning surgery was  $34.1^\circ \pm 15.4^\circ$  and  $32.2^\circ \pm 16.1^\circ$  in eyes that underwent repositioning surgery within 6 days and 7 or more days after the cataract surgery, respectively. In 2 eyes that were treated within 24 hours after cataract surgery, the IOL re-rotated significantly, and additional surgical intervention was required to correct misalignment.

## Discussion

The present study represents the largest case series of patients who underwent surgical repositioning to correct misalignment of toric IOLs. The overall incidence of



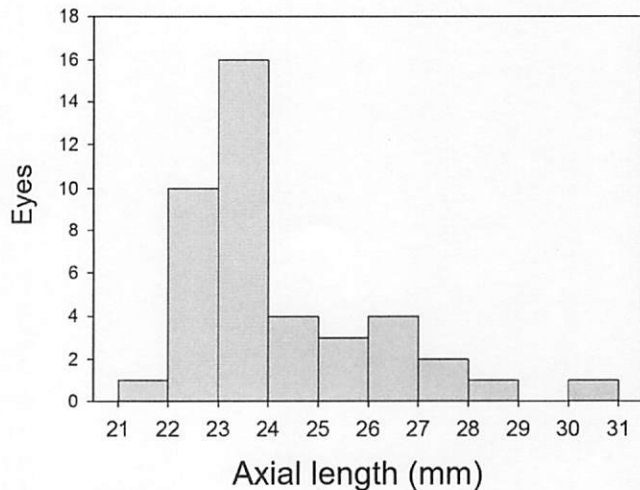


Figure 1. Histogram showing the distribution of axial length.

repositioning surgery was calculated to be 0.653%, which was somewhat lower than those reported in previous studies.<sup>5–14</sup> However, many other studies reported 0% incidence of second surgical procedures.<sup>15–26</sup> In addition, it should be noted that not all patients with a significant amount of misalignment underwent repositioning surgery in our study, because many patients had no symptoms despite IOL misalignment or did not consent to further surgery. Because this was a retrospective review of medical files, the indication for repositioning surgery was not predetermined and was based on the judgment of individual surgeons and patients. The current results reflect the practical situations at clinical sites.

The repositioning surgery was performed at an average of  $9.9 \pm 7.5$  days after the primary cataract surgery and significantly reduced misalignment from  $32.9^\circ \pm 15.7^\circ$  to  $8.8^\circ \pm 9.7^\circ$ . Refractive cylinder was significantly decreased

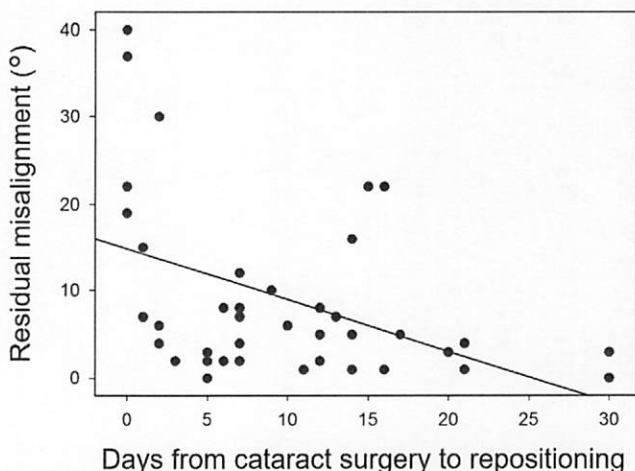


Figure 2. Relationship between the interval from cataract surgery to repositioning procedure and the degree of residual misalignment after repositioning. A significant correlation between them was found (Pearson  $r = -0.439$ ;  $P < 0.001$ ).

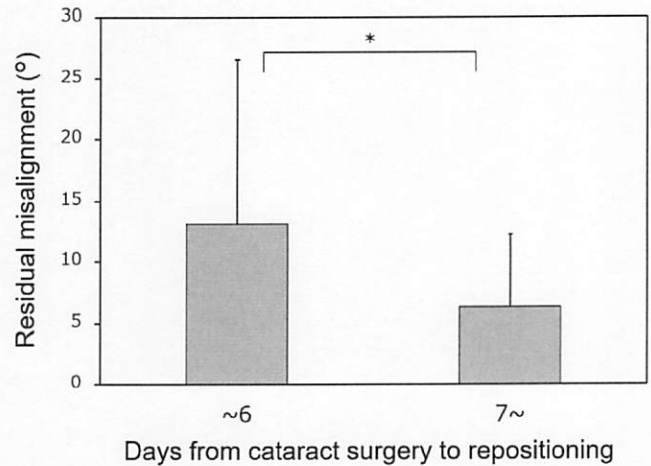


Figure 3. The degree of residual misalignment when repositioning surgery was performed within 6 days or after 7 days after cataract surgery. \*A significant difference between the 2 groups was found ( $13.1^\circ \pm 13.5^\circ$  and  $6.3^\circ \pm 5.9^\circ$ ;  $P < 0.001$ ; unpaired  $t$  test).

from  $2.4 \pm 1.1$  D to  $1.1 \pm 0.8$  D. However, the accuracy of reorientation seems to be related to the timing of repositioning surgery. The surgical outcomes were more favorable when the IOL was repositioned 7 or more days after surgery (Fig 1). In 2 eyes that were treated within 24 hours after cataract surgery, the IOL re-rotated significantly, and additional surgical intervention was required to correct the misalignment. In the case of silicone plate toric IOLs, repositioning surgery was recommended to be performed between the first and second week after primary implantation.<sup>27</sup> It was stated that reorientation should not be done too soon, that is, earlier than 1 week postoperatively, because the lens may rotate again. Reorientation should not be done too late because the lens will be difficult to move because the capsular bag will have already contracted around it.<sup>27</sup> Chang et al<sup>5</sup> performed surgical repositioning in 3 eyes at 5 to 14 days after cataract surgery and obtained good results. Miyake et al<sup>10</sup> reported favorable results of repositioning surgery performed at an average of 8.6 days (range, 2–19 days) after cataract surgery. They also showed that toric IOLs had the greatest rotation in the early postoperative period with little rotation after 1 week.<sup>10</sup> In our study, several IOLs were repositioned at 3 weeks or later after IOL implantation with satisfactory final outcomes. However, we noticed that the IOL was more difficult to rotate and that there was a potential risk of damaging the Zinn's zonules in those patients. Therefore, on the basis of our data suggesting improved accuracy after 1 week and our anecdotal experience that finds rotation to be more challenging later on, we suggest that if repositioning surgery is considered it should be performed between 1 and 3 weeks after the primary IOL implantation.

### Study Limitations

The present study has several limitations. First, being retrospective in nature, there was no predetermined common

indication for repositioning surgery. The repositioning surgery was indicated when the surgeons judged that visual function of the patients would be improved by correcting IOL axis misalignment and the patients consented to the secondary surgical intervention. When there was no patient's consent, further treatment was not performed. Thus, inferences about the true rate and degree of IOL rotation cannot be drawn from this study. Second, the timing of repositioning surgery was not arranged or randomized. Third, we did not analyze the details of misalignment. Misalignment of the toric IOL can be caused by inaccurate placement of the IOL during surgery, rotation of the IOL after surgery, or both. We assumed that inaccurate IOL placement was not a major contributing factor because only experienced surgeons were involved in the present study, and postoperative rotation was a dominant factor. Further studies are needed to elucidate these points. Fourth, the final orientation measurement was not obtained at a standard time point. The final alignment was measured at  $7.6 \pm 5.0$  weeks after the repositioning surgery, leaving open the possibility that IOLs may rotate in the longer term. Recently, however, we reported that the greatest misalignment of toric IOL occurs within 1 hour after cataract surgery, and little rotation is seen from 1 day to 1 year postoperatively.<sup>28</sup> Thus, it is unlikely that the lenses will undergo significant rotation after our follow-up period.

We found that the incidence of repositioning surgery of toric IOLs was 0.653% in our study population. The repositioning surgery was performed at an average of  $9.9 \pm 7.5$  days (range, 0–30 days) after the primary cataract surgery and significantly reduced misalignment and refractive cylinder. There was a significant negative correlation between the interval from cataract surgery to repositioning surgery and the degree of residual misalignment. More favorable surgical outcomes were obtained when the repositioning surgery was performed 1 week or later after cataract surgery. We recommend the repositioning surgery to be performed after 1 week after IOL implantation.

## References

- Visser N, Bauer NJ, Nuijts RM. Toric intraocular lenses: historical overview, patient selection, IOL calculation, surgical techniques, clinical outcomes, and complications. *J Cataract Refract Surg*. 2013;39:624-637.
- Kessel L, Andresen J, Tendal B, et al. Toric intraocular lenses in the correction of astigmatism during cataract surgery: a systematic review and meta-analysis. *Ophthalmology*. 2016;123:275-286.
- Felipe A, Artigas JM, Díez-Ajenjo A, et al. Residual astigmatism produced by toric intraocular lens rotation. *J Cataract Refract Surg*. 2011;37:1895-1901.
- Ma JJ, Tseng SS. Simple method for accurate alignment in toric phakic and aphakic intraocular lens implantation. *J Cataract Refract Surg*. 2008;34:1631-1636.
- Chang DF. Repositioning technique and rate for toric intraocular lenses. *J Cataract Refract Surg*. 2009;35:1315-1316.
- Holland E, Lane S, Horn JD, et al. The AcrySof Toric intraocular lens in subjects with cataracts and corneal astigmatism: a randomized, subject-masked, parallel-group, 1-year study. *Ophthalmology*. 2010;117:2104-2111.
- Dardzhikova A, Shah CR, Gimbel HV. Early experience with the AcrySof toric IOL for the correction of astigmatism in cataract surgery. *Can J Ophthalmol*. 2009;44:269-273.
- Venkataraman A, Kalpana. Visual outcome and rotational stability of open loop toric intraocular lens implantation in Indian eyes. *Indian J Ophthalmol*. 2013;61:626-629.
- Visser N, Beckers HJ, Bauer NJ, et al. Toric vs aspherical control intraocular lenses in patients with cataract and corneal astigmatism: a randomized clinical trial. *JAMA Ophthalmol*. 2014;132:1462-1468.
- Miyake T, Kamiya K, Amano R, et al. Long-term clinical outcomes of toric intraocular lens implantation in cataract cases with preexisting astigmatism. *J Cataract Refract Surg*. 2014;40:1654-1660.
- Waltz KL, Featherstone K, Tsai L, et al. Clinical outcomes of TECNIS toric intraocular lens implantation after cataract removal in patients with corneal astigmatism. *Ophthalmology*. 2015;122:39-47.
- Kasthurirangan S, Feuchter L, Smith P, et al. Software-based evaluation of toric IOL orientation in a multicenter clinical study. *J Refract Surg*. 2014;30:820-826.
- Lubiński W, Kaźmierczak B, Gronkowska-Serafin J, et al. Clinical outcomes after uncomplicated cataract surgery with implantation of the Tecnis Toric intraocular lens. *J Ophthalmol*. 2016;2016:3257217.
- Bissen-Miyajima H, Negishi K, Hieda O, et al. Microincision hydrophobic acrylic aspheric toric intraocular lens for astigmatism and cataract correction. *J Refract Surg*. 2015;31:358-364.
- Mendicutte J, Irigoyen C, Ruiz M, et al. Toric intraocular lens versus opposite clear corneal incisions to correct astigmatism in eyes having cataract surgery. *J Cataract Refract Surg*. 2009;35:451-458.
- Mingo-Botin D, Munoz-Negrete FJ, Won Kim HR, et al. Comparison of toric intraocular lenses and peripheral corneal relaxing incisions to treat astigmatism during cataract surgery. *J Cataract Refract Surg*. 2010;36:1700-1708.
- Zhang JS, Zhao JY, Sun Q, Ma LW. Distance vision after bilateral implantation of AcrySof toric intraocular lenses: a randomized, controlled, prospective trial. *Int J Ophthalmol*. 2011;4:175-178.
- Freitas GO, Boteon JE, Carvalho MJ, et al. Treatment of astigmatism during phacoemulsification. *Arq Bras Oftalmol*. 2014;77:40-46.
- Gangwani V, Hirschall N, Findl O, et al. Multifocal toric intraocular lenses versus multifocal intraocular lenses combined with peripheral corneal relaxing incisions to correct moderate astigmatism. *J Cataract Refract Surg*. 2014;40:1625-1632.
- Hirschall N, Gangwani V, Crnej A, et al. Correction of moderate corneal astigmatism during cataract surgery: toric intraocular lens versus peripheral corneal relaxing incisions. *J Cataract Refract Surg*. 2014;40:354-361.
- Maedel S, Hirschall N, Chen YA, et al. Rotational performance and corneal astigmatism correction during cataract surgery: aspheric toric intraocular lens versus aspheric nontoric intraocular lens with opposite clear corneal incision. *J Cataract Refract Surg*. 2014;40:1355-1362.
- Titilal JS, Khatik M, Sharma N, et al. Toric intraocular lens implantation versus astigmatic keratotomy to correct astigmatism during phacoemulsification. *J Cataract Refract Surg*. 2014;40:741-747.
- Liu Z, Sha X, Liang X, et al. Toric intraocular lens vs. peripheral corneal relaxing incisions to correct astigmatism in eyes undergoing cataract surgery. *Eye Sci*. 2014;29:198-203.

24. Lam DK, Chow VW, Ye C, et al. Comparative evaluation of aspheric toric intraocular lens implantation and limbal relaxing incisions in eyes with cataracts and  $\leq 3$  dioptres of astigmatism. *Br J Ophthalmol*. 2016;100:258-262.
25. Kamiya K, Shimizu K, Miyake T. Changes in astigmatism and corneal higher-order aberrations after phacoemulsification with toric intraocular lens implantation for mild keratoconus with cataract. *Jpn J Ophthalmol*. 2016;60:302-308.
26. Onishi H, Torii H, Watanabe K, et al. Comparison of clinical outcomes among 3 marking methods for toric intraocular lens implantation. *Jpn J Ophthalmol*. 2016;60:142-149.
27. Novis C. Astigmatism and toric intraocular lenses. *Curr Opin Ophthalmol*. 2000;11:47-50.
28. Inoue Y, Takehara H, Oshika T. Axis misalignment of toric intraocular lens: placement error and postoperative rotation. *Ophthalmology*. 2017;124:1424-1425.

## Footnotes and Financial Disclosures

Originally received: January 5, 2017.

Final revision: June 30, 2017.

Accepted: July 6, 2017.

Available online: August 18, 2017.

Manuscript no. 2017-27.

<sup>1</sup> Department of Ophthalmology, Faculty of Medicine, University of Tsukuba, Ibaraki, Japan.

<sup>2</sup> Inamura Eye Clinic, Kanagawa, Japan.

<sup>3</sup> Inoue Eye Clinic, Okayama, Japan.

<sup>4</sup> Ohashi Eye Clinic, Hokkaido, Japan.

<sup>5</sup> Sugita Eye Clinic, Tokyo, Japan.

<sup>6</sup> Fujita Eye Clinic, Tokushima, Japan.

<sup>7</sup> Miyata Eye Hospital, Miyazaki, Japan.

<sup>8</sup> Division of Ophthalmology, Ryugasaki Saiseikai Hospital, Ibaraki, Japan.

### Financial Disclosure(s):

The author(s) have made the following disclosure(s): T.O.: Grants and personal fees — Alcon, Abbott Medical Optics, Santen, Senju, Otsuka, NIDEK, Kowa.

M.I.: Speakers honoraria — Alcon, Abbott Medical Optics, Hoya, Pfizer, Santen, Senju, Otsuka, Japan Focus, Carl Zeiss, Qualitas.

Y.I.: Grants — Alcon, Abbott Medical Optics, Santen, Senju, Otsuka; Speakers honoraria — Pfizer, Kaneka Medix, NIDEK, Machida Endoscope, Nitto Medic, Kowa.

T.S.: Personal fees — Alcon, Abbott Medical Optics, Qualitas; Grants — Santen, Senju.

Y.F.: Speakers honoraria — Alcon, Abbott Medical Optics, Hoya, Senju, Kowa, Ohtsuka, Pfizer; Grants — Santen.

K.M.: Grants and personal fees — Alcon, Abbott Medical Optics, Hoya, Santen, Senju, Sucampo Pharma, GlaxoSmithKline, Ohtsuka, Kissei, Becton Dickinson, Shionogi, Novartis, Wakamoto, MSD, Pfizer, STAAR.

S.N.: Grants and personal fees — Abbott Medical Optics, Santen; Personal fees — HOYA.

### Author Contributions:

Conception and design: Oshika, Inamura, Inoue, Ohashi, Sugita, Fujita, Miyata, Nakano

Data collection: Oshika, Inamura, Inoue, Ohashi, Sugita, Fujita, Miyata, Nakano

Analysis and interpretation: Oshika

Obtained funding: Not applicable

Overall responsibility: Oshika

### Abbreviations and Acronyms:

D = diopters; IOL = intraocular lens.

### Correspondence:

Tetsuro Oshika, MD, Department of Ophthalmology, Faculty of Medicine, University of Tsukuba, 1-1-1, Tennoudai, Tsukuba, Ibaraki, 305-8575 Japan. E-mail: oshika@eye.ac.